



For more information on head and neck oncology please contact:

sydney head & neck cancer institute

royal prince alfred hospital
room 6.10, level 6
gloucester house
missenden road
camperdown nsw 2050
phone: (02) 9515 7537
fax (02) 9515 7483
email: headandneck@email.cs.nsw.gov.au
web: www.shnci.org

The printing of this booklet was sponsored by the generous support of Blake Dawson Waldron Solicitors and J.S. McMillan Printing Group.



neck lumps

a diagnostic guide for general practitioners

the sydney head and neck cancer institute



Professor Christopher J O'Brien MS FRACS

The Sydney Head & Neck Cancer Institute
Sydney Cancer Centre
Royal Prince Alfred Hospital
University of Sydney

introduction

The purpose of this booklet is to provide information to the General Practitioner about common neck lumps, their clinical features and how they should be investigated. Lumps and swellings in the neck are seen frequently in general practice and often it is easy to make a diagnosis based on clinical examination alone. Commonly however, investigations are required to clarify the diagnosis and, in particular, exclude or confirm a diagnosis of malignancy. The most important issue is that the possibility of a malignant diagnosis is not overlooked and that the pathway of diagnosis and referral of patients with cancer in the neck is appropriate.

Neck lumps in children are common but rarely malignant, frequently representing reactive lymph node enlargement. In adults on the other hand benign reactive lymph node enlargement is uncommon and the following rule should apply.

An adult with a lump in the lateral neck has cancer until proved otherwise.

Adults with lateral neck lumps should be investigated therefore to exclude malignancy – they should not be subjected to lengthy trials of observation or antibiotic therapy. A diagnosis can be readily made in the vast majority of cases when the following are used judiciously:

1. Thorough clinical history
2. Physical examination
3. Fine needle aspiration biopsy (FNAB)
4. CT Scan

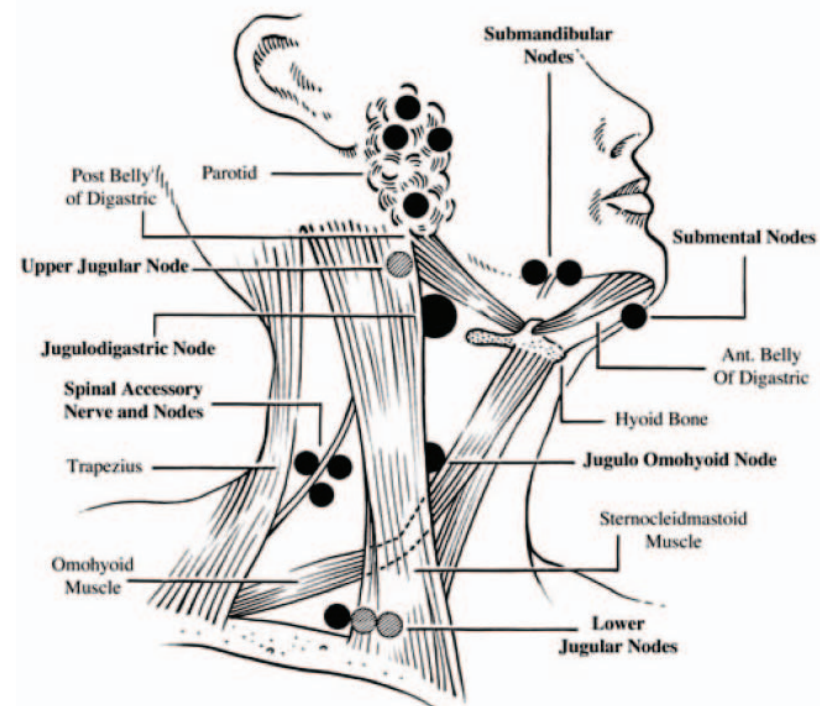
When a diagnosis of cancer in the neck is made, the patient should be referred to a head and neck surgeon or oncologist who participates in a multi-disciplinary clinic.

lateral neck swellings

History and physical examination are fundamental to making an early and correct diagnosis. The age of the patient, the length of time the swelling has been present and its position in the neck are all helpful. Children commonly present with a short history of tender, enlarged lymph nodes in the jugulodigastric area (**tonsillar lymph node**) suggesting an infective process, or multiple small non-tender nodes in the posterior triangle, suggesting a subclinical viral infection. Cystic swellings are usually congenital and can be due to **lymphangioma** (cystic hygroma) or **haemangioma**. Localised swellings in the thyroid gland or parotid in children are uncommon but malignancy needs to be excluded.

Adolescents also often develop acute inflammatory lymphadenopathy, particular in the jugulodigastric region and this can be bacterial or viral (e.g. **glandular fever**). Adolescents can develop lymphoma, particularly **Hodgkin's Disease**, and prominent lymph nodes which are non-tender and progressively enlarging should be treated with suspicion. **Branchial cysts** are seen mainly in young adults, presenting in the jugulodigastric region. They are not developmental but are probably due to epithelial cell "rests" in a lymph node.

DIAGRAM OF TRIANGLES, LYMPH NODE LEVELS AND NORMAL LYMPH NODES IN THE NECK



The diagrammatic representation on the right demonstrates the distribution of the lymph nodes in the neck along with the main muscular anatomy.

lateral neck swellings

Multiple small nodes, commonly occurring in the posterior triangle, again tend to be due to subclinical viral infections.

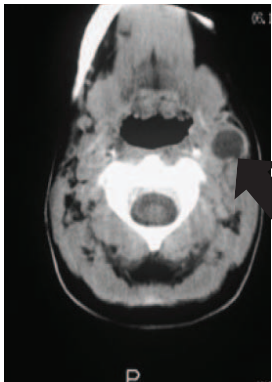
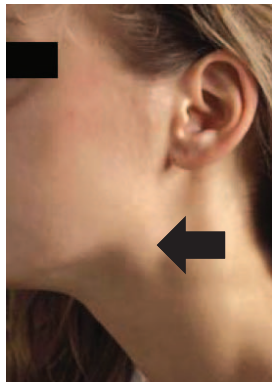Clinical evaluation of adults with lateral neck lumps is aimed at excluding cancer.

Middle-aged adults who smoke and drink are at high risk of having mucosal cancers of the oral cavity, oropharynx or laryngopharyngeal region. Associated symptoms like referred ear pain, voice change, dysphagia or weight loss should be sought.

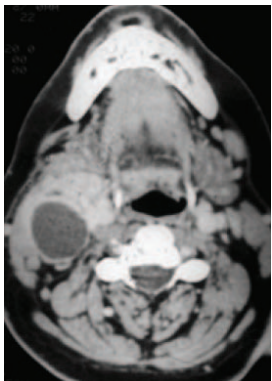Always ask for a history of a previously treated cancer of the skin, lip, oral cavity and other mucosal sites.

Asian patients with enlarged neck nodes will frequently have either nasopharyngeal cancer or tuberculosis.

Elderly patients, especially those with fair skin, may have a history of previous skin cancer and a lump in the neck, especially in the submandibular region, the upper neck or tail of parotid that may represent metastatic skin cancer, especially SCC or melanoma.

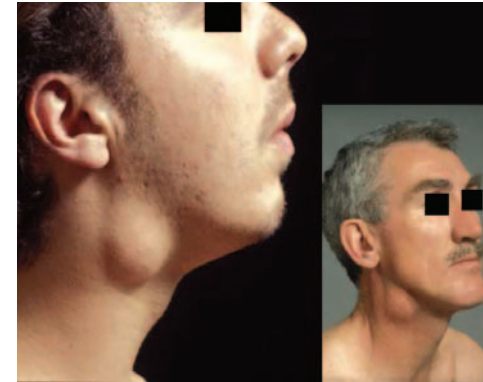


This 19 year old girl had a two-week history of a painless swelling in the left jugulodigastric region. FNAB demonstrated benign squamous cells, cellular debris and cholesterol crystals. CT scan demonstrated a well circumscribed cystic mass, anterior to the sternomastoid muscle. This is a typical **branchial cyst**.

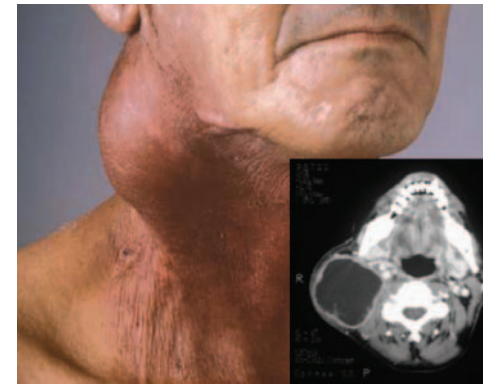


This young woman had a one-week history of a rapidly enlarging mass in the upper right neck with localised tenderness. The CT scan again demonstrates a well-circumscribed unilocular cyst, with a smooth wall -**branchial cyst**.

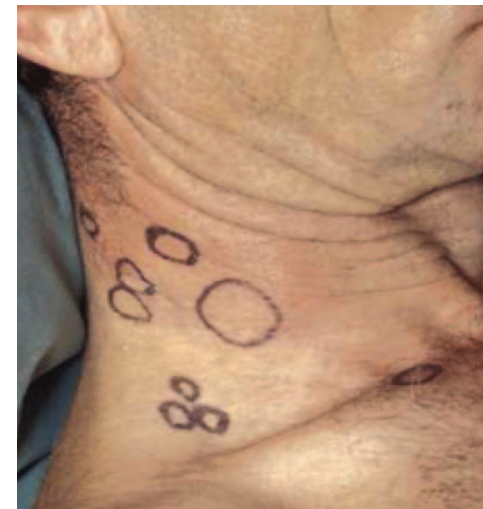This young man has a prominent painless lymph node in the jugulodigastric region. Fine needle aspiration biopsy indicated a diagnosis of **Hodgkin's Disease**. The 40 year old man (inset) has a lump in an identical position, also painless and present for months. Fine needle aspiration biopsy confirmed the diagnosis of **metastatic squamous cell carcinoma from a tonsil cancer**. He was a non smoker.



NOT ALL CYSTIC MASSES IN THE NECK ARE BENIGN. The man on the right is 60, a heavy smoker and presents with a hoarse voice and large mass in the right upper neck. Fine needle aspiration biopsy showed necrotic debris and the CT scan demonstrates a unilocular cystic mass. The cyst wall is irregular and this is **metastatic squamous carcinoma**, which has undergone cystic degeneration. The primary cancer was in the hypopharynx.



This man has **nasopharyngeal carcinoma with multiple metastatic lymph nodes** in the posterior triangle, bounded by the clavicle below, sternomastoid muscle anteriorly and the trapezius posteriorly. Nasopharyngeal carcinoma is really the only mucosal cancer which can spread to the posterior triangle, without nodes elsewhere in the neck. Metastatic **skin cancer and lymphoma** could also present with this distribution of nodes.



Beware of cystic lateral neck masses in adults. They may be metastatic SCC with cystic degeneration.

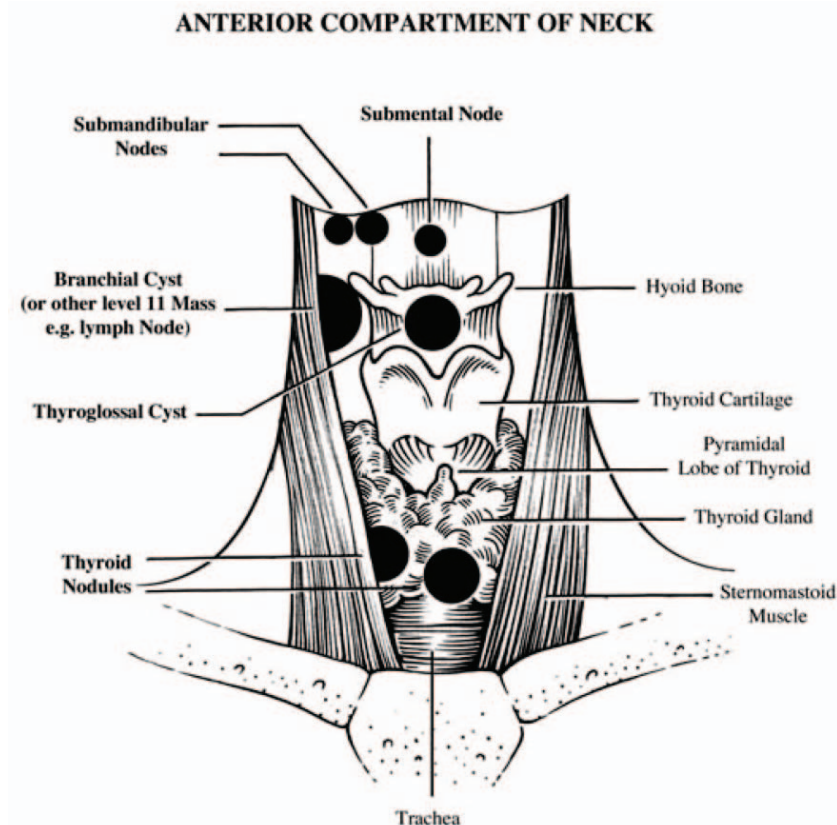
anterior neck swellings

Lumps in the anterior neck compartment can occur in the submental region (below the chin) or the upper or lower anterior neck. Lumps in the submental triangle are usually enlarged lymph nodes and may be reactive or neoplastic.

In young adults **Hodgkin's Disease** needs to be excluded while in older adults metastatic cancer, particularly from **cancers of the lip** or from an asymptomatic **floor of mouth cancer** should be considered.

Swellings around the hyoid bone are most likely to represent a **thyroglossal duct remnant**. About 80% of these lie below the level of the hyoid bone and an important clinical feature is that they elevate with protrusion of the tongue. **Dermoid cysts** can also occur in the midline, anywhere from the chin to the jugular notch. These are congenital, benign and usually contain thick white paste-like material.

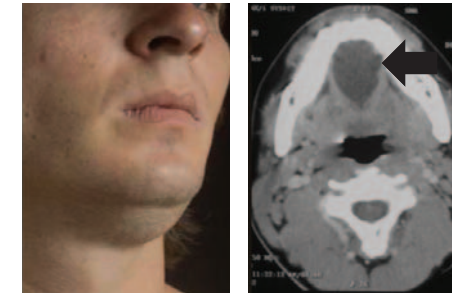
The commonest swellings in the central compartment of the neck involve the **thyroid gland**. These are rarely in the midline unless the nodule occupies the isthmus or pyramidal lobe and so they tend to sit to one side of the midline.



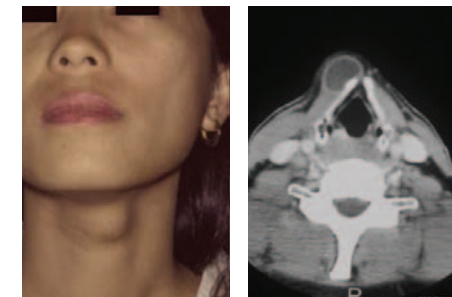
The important clinical feature of a **thyroid nodule** is that the lump elevates with swallowing. When there are multiple thyroid lumps (multinodular goitre) the risk of malignancy is low, about 5%, however the incidence of malignancy is higher in a solitary thyroid lump, especially when larger than 4cm and in men.

Solitary or dominant thyroid nodules should be investigated by FNAB and serum TSH. Ultrasound and nuclear scanning contribute little to excluding malignancy.

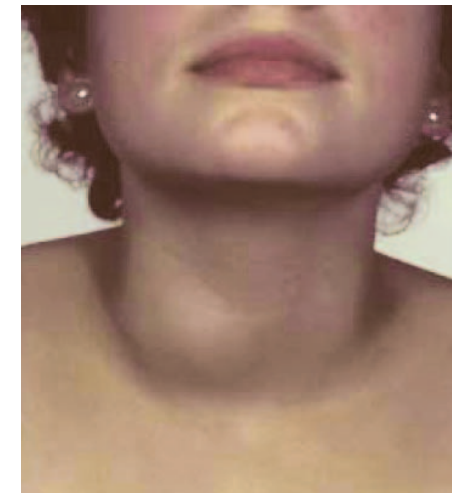
The young man on the right had a firm, but not hard submandibular swelling which had been present for 5 years. The CT scan on the right demonstrates a midline **dermoid cyst**. This is a well localised benign congenital lesion.



This young woman, aged 25, has a well localised swelling just below the hyoid bone, which elevates on protrusion of the tongue. The CT scan on the right is from another patient but demonstrates identical pathology of a well circumscribed cystic structure lying anterior to the thyroid cartilage - **thyroglossal cyst**.



This young woman has a prominent right **thyroid nodule**. The appropriate investigations are FNAB and serum TSH.



submandibular region

The main anatomical structures in the submandibular triangle are the submandibular salivary gland and the submandibular lymph nodes, which lie anterior and posterior to the facial vessels (so called pre-vascular and post-vascular nodes).

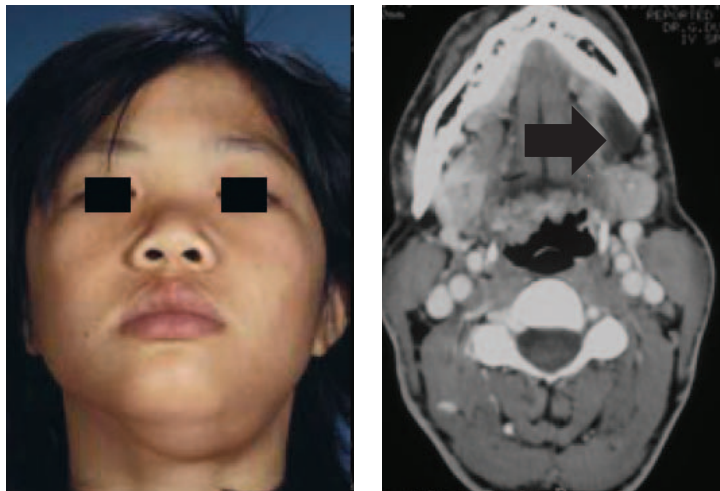
These nodes are a common site of reactive enlargement in children and adolescents but they may also be a site of **metastatic disease** from **cancers of the lip** or the **skin of the face** and less commonly, **oral cavity cancer**.

Swellings of the submandibular salivary gland are usually acute, related to eating and are due most commonly to **a stone obstructing the submandibular duct**. Painless, progressive swelling of the submandibular gland raises the possibility of a tumour.

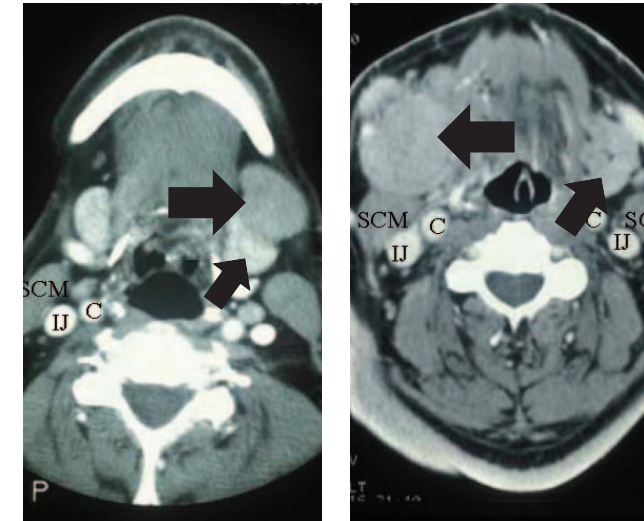
In contrast to parotid tumours, **at least 50% of tumours of the submandibular salivary gland are malignant**.

An uncommon submandibular swelling, which frequently poses diagnostic difficulty, is a **plunging ranula**. This is due to extravasation of mucoid saliva from a disrupted sublingual gland in the floor of the mouth. Instead of the mucoid saliva collecting in the floor of the mouth and causing a swelling under the mucosa (a ranula) the mucous makes its way into the subcutaneous space in the submandibular region. **Removal of the sublingual gland via the mouth is the curative operation for a plunging ranula.**

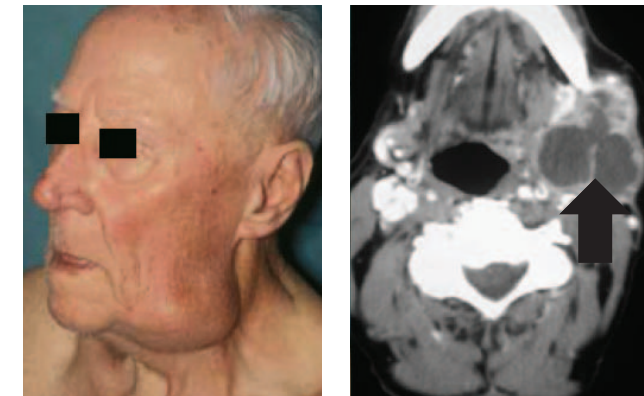
This boy, aged 14, presented with a cystic mass in the left submandibular region. Needle biopsy demonstrated the presence of mucoid material and the CT scan shows a cystic mass lying anterior to the left submandibular salivary gland. This is a typical plunging ranula and is due to extravasation of mucoid saliva from the left sublingual gland.



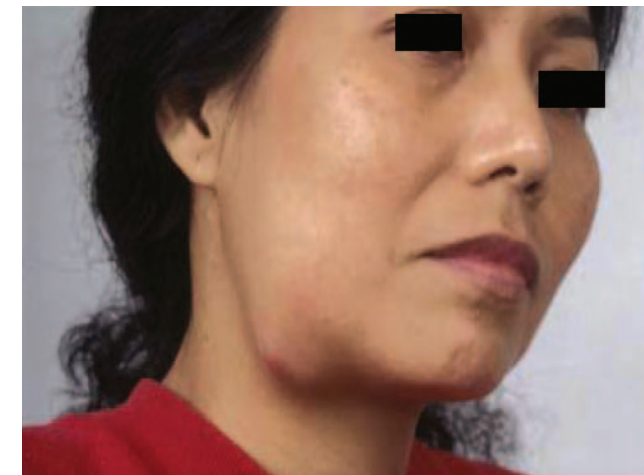The CT scan on the right demonstrates a pathologically enlarged lymph node (large arrow) lying in front of the left submandibular salivary gland (small arrow). Fine needle biopsy demonstrated atypical lymphocytes and the lymph gland was excised. The diagnosis was **non-Hodgkin's Lymphoma**. The CT scan on the far right shows a pathologically enlarged right submandibular salivary gland (large arrow) while the submandibular salivary gland on the left (small arrow) is of normal size. The mass on the right was painless and slowly growing over two years. Needle biopsy suggested a diagnosis of **pleomorphic adenoma** and this was proven on excision.



This elderly man has a large left submandibular mass. An SCC of the cheek was removed a year earlier. FNAB showed metastatic SCC and the CT scan demonstrates a large cystic mass with a septum, consistent with **metastatic cancer**.



This 45 year old Asian woman, recently migrated to Australia, presented with a suppurating mass in the right submandibular region. A diagnosis of tuberculosis was made following culture of tissue from the mass.

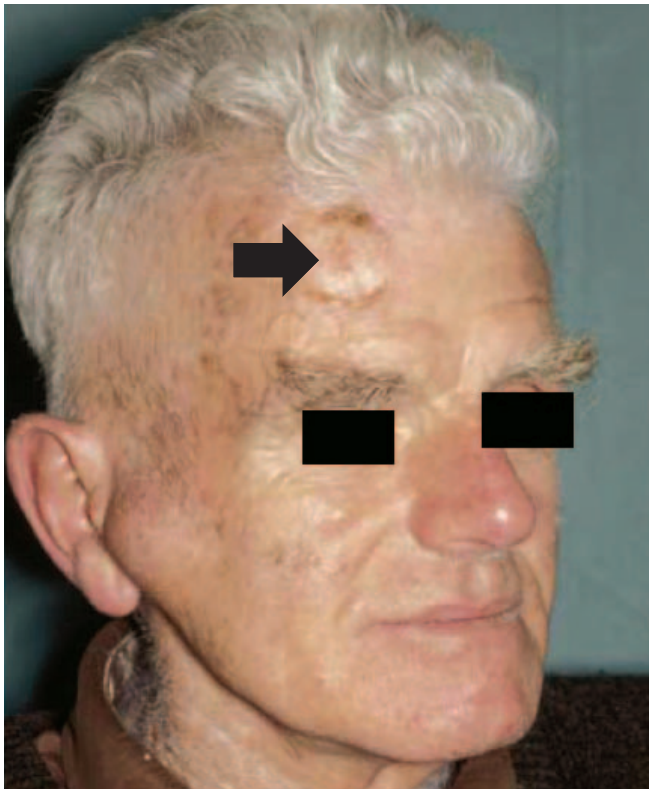

swellings around the parotid region

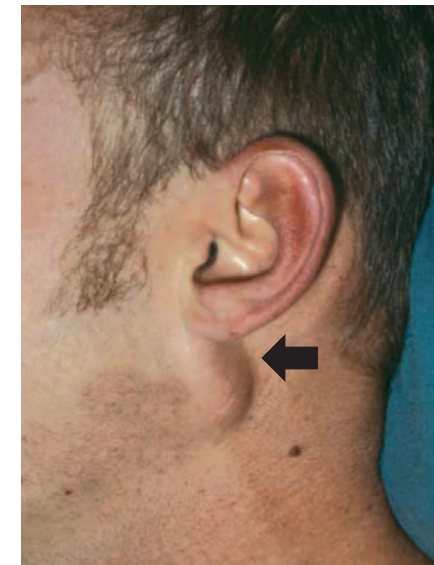In contrast to the submandibular gland, infective and inflammatory swellings of the parotid gland are not particularly common.

Viral infections (e.g. mumps) and bacterial infections (frequently secondary to salivary obstruction) can occur and the history usually is of acute pain and swelling. Tumours tend to have a longer history and are usually painless. Over 85% of primary parotid tumours are benign, usually pleomorphic adenoma in younger adults and Warthin's tumour in older adults. **The commonest malignant parotid tumour which we see in Australia is metastatic skin cancer, either SCC or melanoma.**

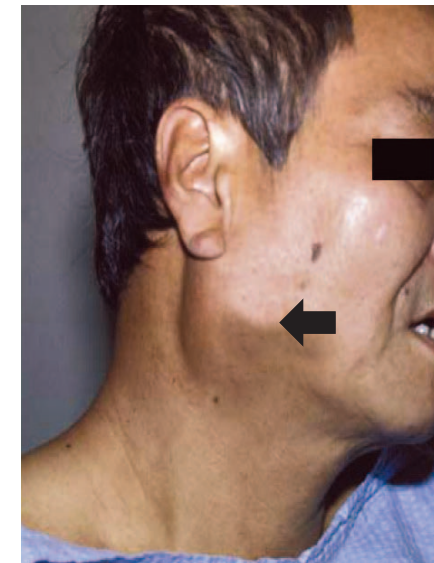Excision biopsy of lumps around the parotid region should not be carried out. If the lump proves to be a parotid malignancy, inappropriate excision biopsy can lead to great difficulty in subsequent treatment and predispose to recurrence.



This fair haired man aged 70 previously had a cutaneous SCC removed from the right side of the forehead (arrow) and presented 6 months later with a prominent painless mass in the right pre-auricular region. This is metastatic SCC involving a parotid lymph node. This is the commonest **parotid malignancy** seen in Australia.



The young man on the right was aged 20 and presented with a one-year history of a painless lump at the angle of the jaw. This is a parotid mass and needle biopsy suggested a diagnosis of **pleomorphic adenoma**.



The man on the right aged 58 has a two-year history of a painless slowly growing mass at the angle of the jaw. Needle biopsy suggested a diagnosis of **Warthin's tumour**.

The key investigations for neck lumps, following history and physical examination, are fine needle aspiration biopsy (FNAB) and CT scan with contrast. Ultrasound contributes little to the diagnosis of neck lumps. It is useful in evaluating the thyroid gland to determine whether or not a nodule is solitary or part of a multinodular goitre. Ultrasound is also useful as an aid during FNAB when a neck lump is small or difficult to feel.